

CT2TEE – a novel, internet-based simulator of transoesophageal echocardiography in congenital heart disease

CT2TEE – internetowy symulator echokardiografii przezprzelykowej we wrodzonych wadach serca

Aleksander Kempny¹, Adam Piórkowski²

¹ Marienkrankenhaus Soest, Germany

² Department of Geoinformatics and Applied Computer Science, AGH University of Science and Technology, Krakow, Poland

Abstract

Background: Echocardiography is one of the most important diagnostic tools in cardiology. The two most widespread modes of echocardiography are transthoracic (TTE) and transoesophageal (TEE) echocardiography, both requiring extensive training. In TEE the manual skills seem to be less important, but it is more challenging for the trainee to imagine the orientation of the cutting planes in space. This becomes more complicated, even for an experienced echocardiographer, in patients with congenital heart disease. There is a growing interest in TEE simulators. All of them are, however, manikin based and their use is limited to only a few medical centres.

Aim: To develop an internet-based TEE simulator offering interactive training in cases with and without congenital heart disease.

Methods: Because of high spatial resolution we use data from ECG-triggered heart computed tomography (CT) to build the 3D heart model. On every CT image the oesophagus has to be marked and the greyscale values converted in order to mimic the tissue greyscales seen in TEE. After such preparations the 3D set created from CT data can be cut in any plane. The trainee can use the slider buttons in the simulator interface to freely steer the virtual TEE probe. While setting the desired TEE plane the application conducts calculations in order to simulate the typical sonographic artefacts.

Results: We were able to construct an application allowing a TEE simulation based on CT data. There are two versions of the simulator. The first one has to be downloaded to a personal computer together with the CT data. The second one is internet based and freely accessible on the project's web page (www.ct2tee.agh.edu.pl). It doesn't offer real time simulation, but is sufficient to obtain all possible views in the TEE. There are currently three data sets, two with congenital heart disease, and further development of the database and simulator is planned.

Conclusions: The CT2TEE simulator, described in this paper, is the first fully interactive, internet-based TEE simulator. It can be a training tool both in learning TEE basics and in congenital heart disease.

Key words: transoesophageal echocardiography, simulator, computed tomography

Kardiologia Polska 2010; 68: 374-379

Introduction and literature

Echocardiography is one of the most important tools in cardiology, providing information concerning heart anatomy and function, and thereby helping to detect or exclude diseases and to guide the surgical and medical treatment. There are many other imaging modalities allowing visualisation of the heart, for example magnetic resonance (MR) and computed tomography (CT), but echocardiography remains in many ways unique.

The two most widespread modes of echocardiography are transthoracic (TTE) and transoesophageal (TEE) echocardiography, both requiring extensive training. In the

first one there are defined several standard examination planes. Proper visualisation requires however different angulations of the TTE probe, making extensive hands-on training necessary.

In TEE manual skills seem to be less important. After oesophageal intubation the probe slides along the oesophagus, while pushing or pulling it. It can also be turned right or left, and by pushing the buttons or turning the wheels on the probe's handle the probe's angulation and deflection angles can be changed. All these manoeuvres require less manual skill than in TTE, but it is challenging for the trainee to imagine the orientation of

Address for correspondence:

Aleksander Kempny MD, PhD, Marienkrankenhaus Soest, Widumgasse 5, 59494 Soest, Germany, e-mail: kempny@gmail.com

the cutting planes in space. This becomes more complicated, even for an experienced echocardiographer, in patients with congenital heart defects and therefore changed heart anatomy and often different situs. TEE is a semi-invasive procedure, is unpleasant for conscious patients and therefore should be performed relatively quickly and cannot be repeated or conducted only for educational purposes.

Before being able to independently perform and interpret the echocardiographic examinations the physician should learn and practise in a high volume centre, which is time-consuming and does not warrant contact with patients with rare diseases, including congenital heart defects [1-3].

Nowadays simulators are increasingly used in medical education, especially in endoscopy [4], anaesthesia [5], surgery [6, 7] and also ultrasound [8], with encouraging results. They allow one to flatten and shorten the learning curve and to ensure acquisition of the core skills [9]. The PubMed search revealed however only two projects describing the use of TEE simulators. Both of them are based on a manikin with a TEE-like looking probe attached to a personal computer (PC) equipped with special software [10, 11]. The use of these simulators is and will be limited to only a few centres. Assuming that not all physicians learning echocardiography will attend a TEE course in training centres equipped with a manikin-based simulator and that many trainees try to learn the basics from a book, there is a place for a software-based simulator that can also be used at home.

We therefore developed a free, internet-based simulator of transoesophageal echocardiography in which the TEE probe can be steered with the mouse and keyboard.

Transoesophageal simulator (methods and results)

The CT2TEE simulator consists of a core CT2TEE application and a databank of CT sets.

Because of the unlimited number of cross-sectional planes in TEE, to create a two-dimensional (2D) TEE

simulation a three-dimensional (3D) heart model has to be created in the CT2TEE application first. This can be done theoretically with many heart imaging modalities. The TEE simulator described by Weidenbach et al. uses the data collected during 3D transthoracic echocardiography [12, 13]. This however has several limitations. First of all the resolution of such 3D data is markedly lower than in 2D echocardiography. There are also many heart structures that because of sonographic artefacts in the transthoracic view cannot be seen in such TEE reconstruction.

Because of much higher spatial resolution we decided to use data from ECG-triggered CT of the heart to build the 3D heart model in our simulator [14].

The CT set consists of a block of images stored in a lossless 'Digital Imaging and Communications in Medicine' (DICOM) data format [15]. All of them are situated in parallel planes and the distance between them is encoded within the DICOM format. Each consecutive slide of the CT data set is taken as the next surface for the value Z ; values (X, Y) are the pixels of a single image surface (Figure 1).

Before starting the TEE simulation the set of CT images has to be prepared. On every CT image the oesophagus has to be marked and the greyscale values converted in order to mimic the tissue greyscales seen in TEE (Figure 2).

After such preparations this 3D set can be cut in any plane, as in the real TEE. Both versions of the simulator, described later, have a similar interface, allowing one to slide the virtual probe along the oesophagus, turn it, and change the plane angulation and deflection of the probe's tip (Figure 3). After setting the desired TEE simulator plane the application conducts for each view calculations in order to adjust the greyscale to make it similar to TEE views and to simulate the typical sonographic artefacts.

There are two versions of the simulator, both based on the same core 'CT2TEE application'. In the first one, based on the 'thick client' principle, the user has to download the DICOM CT data set, consisting of hundreds of megabytes, and install the CT2TEE application on a personal computer. In this version while moving the sliders used for steering the TEE probe the user sees a real time simulation with

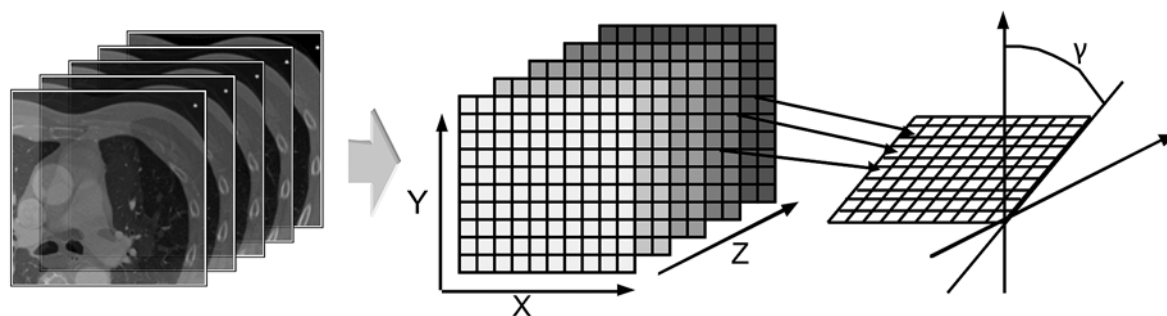


Figure 1. Set of CT images, shown on the left, is used to build a 3D model. After that, the 2D reconstruction can be made in every plane

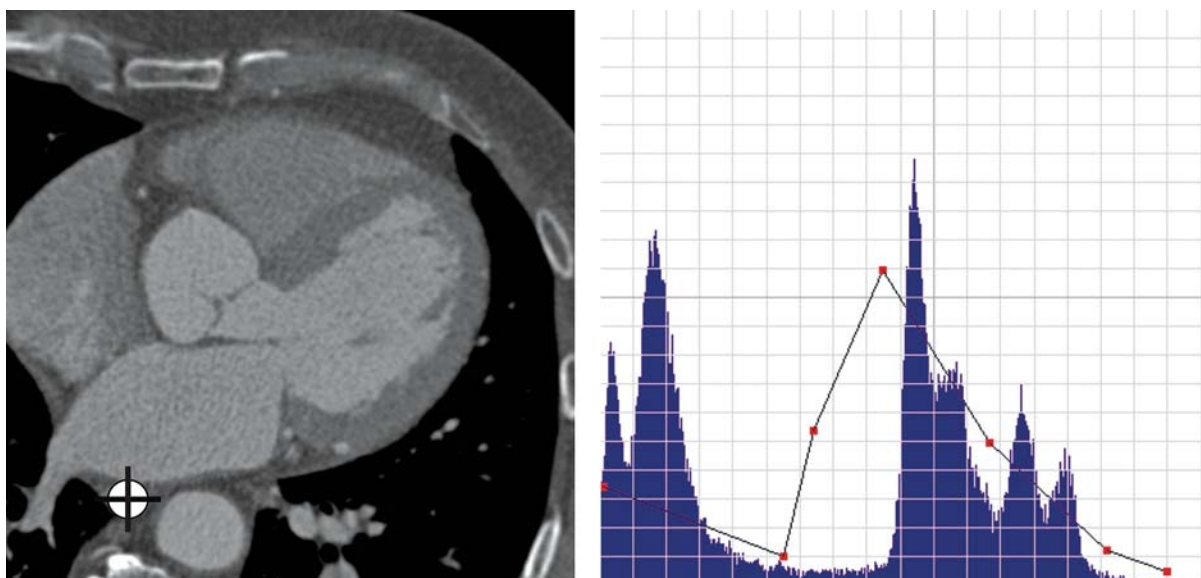


Figure 2. Several steps are necessary to prepare a CT set for the TEE simulation. On every CT image the position of the oesophagus has to be marked (picture on the left). The tissues have different brightness in CT and TEE. For example, blood in CT after the application of contrast agent is very bright, whereas in TEE it is almost black. Adjustment of the histogram of CT images, shown in the right picture, makes them similar to TEE images

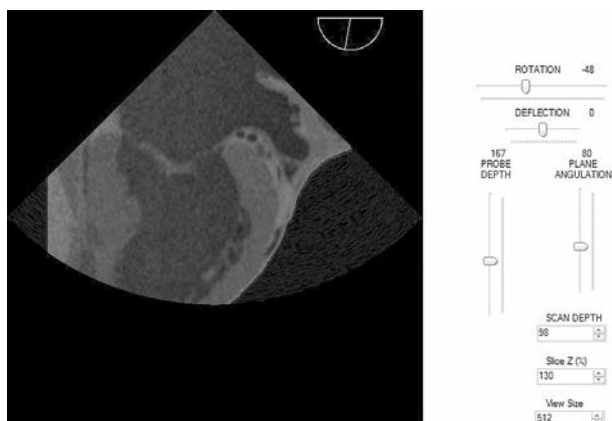


Figure 3. The virtual TEE probe is steered with several sliders. The slider 'probe depth' reflects the probe position in the oesophagus. Moving the slider up moves the virtual TEE probe toward the stomach and moving it down pulls the TEE probe. The default position of the 'rotation' slider is 0, meaning that the ultrasound beam spreads in the direction from the oesophagus to the sternum. Moving the slider right turns the probe clockwise and moving it left turns the TEE probe in the opposite direction. Similar as in real TEE, changing the setting of the 'plane angulation' and 'deflection' sliders respectively changes the angulation of the visualization plane and bends the tip of the probe. Changing the plane angulation also changes the position of the arrow on the indicator situated in the right upper corner of the simulation-view

minimal time resolution of at least 15 frames per second. The second version is based on the 'thin client principle' and is freely accessible via the internet on the project webpage (www.ct2tee.agh.edu.pl). In this version the CT2TEE application runs on a server, where also the CT data are stored, and sends the reconstruction of the view in the desired plane. The user has access to the server via the internet (www) and doesn't have to download the CT data sets and the application itself. In the internet-based version, however, the trainee doesn't see a smooth real time simulation while changing the settings of the TEE probe. Because of insufficient speed of internet connections the new view is seen at once, as a single image, after releasing the slider button. In both versions, however, similar TEE views are reconstructed, which resemble the real TEE view (Figure 4).

There are currently three sets of data available online. The 'normal set' is reconstructed with the use of the CT data set showing no major abnormalities. It can be helpful for beginners in setting the standard views but also for advanced users wanting to improve their skills. The second one is obtained in a patient with anomaly of the coronary arteries (Figure 3) and the third one with unroofed coronary sinus and persistent left superior caval vein. These sets can be helpful for more experienced users learning at home or preparing for TEE in a patient with a similar heart defect. The number of cases in our database is currently limited by the hardware. Every data set has to be stored on fast random access memory (RAM) while performing the simulation on the server (Intel Xeon 3040, 1.86 GHz, BUS Speed 266 MHz). The CT2TEE

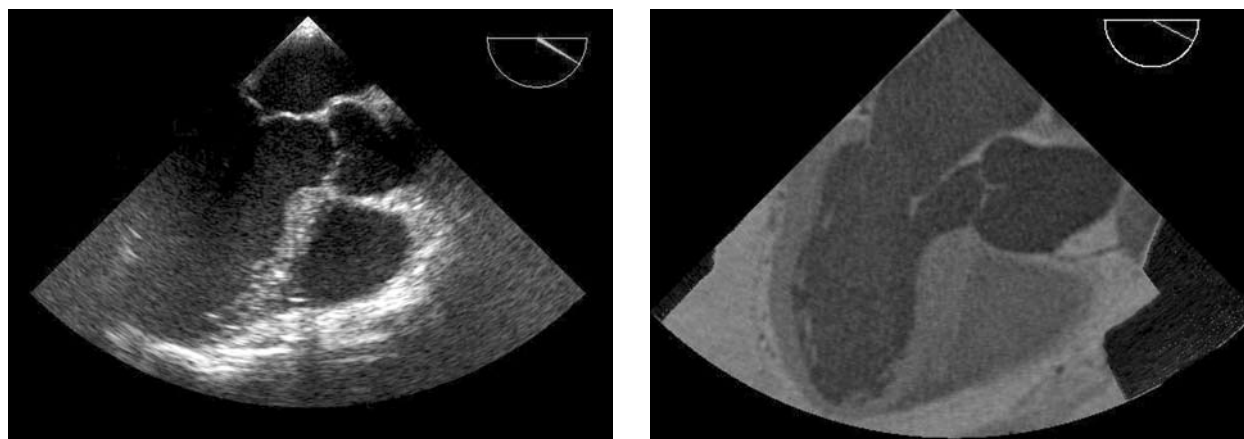


Figure 4. Comparison of the real TEE view (on the left) and similar view in the CT2TEE internet-based simulator (on the right). The greyscale values for tissues are similar, but not identical. Of note is however markedly higher spatial resolution in the right picture, where small structures, for example coronary arteries, are clearly visible

application running on the server is also demanding and allows parallel access for only approximately 50 users. The calculations are performed on the server, so that the minimal requirements for the user's PC are not demanding and include a 200 MHz processor, 256 MB RAM, MS Internet Explorer 6.0 / Mozilla 3.0 or equivalent browser with JavaScript support.

Discussion and summary

The CT2TEE simulator is the first internet-based TEE simulator described in the literature. In contrast to other TEE simulators CT2TEE is the only one that is also free and does not require additional hardware. Nowadays, with the increasing demand for TEE and therefore need for staff training, an additional teaching tool might be of special interest.

Transoesophageal echocardiography is a user-dependent imaging modality. Proper steering of the probe, spatial orientation and knowledge of potential pathologies play a pivotal role. Simulator training cannot replace traditional learning methods in the learning process but can address the main obstacles in the learning process.

One of the main problems when learning TEE is the orientation in space. It can be challenging, even for echocardiographers having experience in TTE, to imagine a 3D heart model seen and then cut in 2D from the oesophagus, as in TEE. Experience in TTE is however helpful. It has been addressed in the recent guidelines of the European Association of Echocardiography (EAE), recommending 75 TEE examinations for users having a basic level of experience in TTE and 125 TEE examinations for those without experience in TTE and wanting to receive EAE accreditation to perform TEE independently [1]. Learning from a book or attending a TEE course with little hands-on training will not improve the

ability to properly steer the TEE probe in order to visualize all heart structures. Training with the online, interactive CT2TEE simulator with consequent setting of all the standard TEE views can however improve those practical skills. Because of the use of CT data in our project, offering high spatial resolution, even trifling heart structures can be visualised. Small objects, such as coronary arteries, or structures not always seen completely in TEE, such as lung veins and pulmonary arteries, can be clearly seen in CT2TEE. Their evaluation in different views in this simulator can facilitate further assessment in real patients.

Even after completing training in TEE it can still be challenging to perform TEE in patients with major structural heart abnormalities. There is nowadays a growing number of adult patients with congenital heart defects in whom correction surgery has been conducted in childhood [16]. This group of patients, although small, requires frequent evaluation and professional expertise, while learning possibilities in the form of echocardiographic courses, workshops and books are still very limited. The current guidelines of the European Association of Echocardiography point to the fact that the trainee should not only complete the required number of TTE and TEE examinations during the training, but also to the need for a well-balanced mix of pathology. The EAE guidelines do not define, however, the number of studies that have to be performed during the training in patients with congenital heart disease.

The guidelines of the American College of Cardiology and the American Heart Association advise additional training in a special facility and performing interpretation of a further 75 TEEs in order to acquire proficiency in TEE in complex congenital heart defects [17]. Such training is however time-consuming, and there are only a few centres where TEE is conducted frequently enough to offer such training.

It is important for the echocardiographer to have experience in congenital heart defects for two main reasons. The first one is that all echocardiographers are expected to be ready for incidental findings in patients in whom echocardiography is being done for different reasons. It can sometimes have very important implications. For example, an attempt to implant a cardiac stimulator pacing lead through the left subclavian vein in case of a persistent left superior caval vein can lead to unexpected complications [18]. During the training with CT2TEE the trainee can face such rare defects and experiment in a risk-free environment with different probe settings, therefore speed up the learning process and thus be ready for the unexpected in the real world.

The second reason is that most patients with congenital heart disease require regular echocardiographic evaluation, mostly with TTE, but sometimes also with TEE [19]. For example, patients with transposition of the great arteries who have undergone Mustard or Senning operation can occasionally require evaluation of the baffles at the atrial level [20]. In case of such complex heart morphology, training with CT2TEE prior to the real TEE can be very helpful. Because of frequent use of CT in patients with congenital heart disease a database with a wide spectrum of such cases can be easily created [21, 22].

The CT2TEE project has existed for several months and is still dynamically developing. The simulator currently has several limitations. We still haven't developed a TEE probe simulator. Navigation with the mouse and keyboard is sufficient to obtain all necessary views, but does not develop the manual skills in handling the real TEE probe. In contrast to real echocardiography, in our simulator the heart doesn't move. Further development with application of algorithms for picture deformation can set the myocardium and valves in motion. Also, designing a simple USB-based simulator of the TEE probe for personal use will in the future help to make the simulator more realistic. As in all other TEE simulators, Doppler features are not available either, but it is planned to use dynamic data sets from cardiac magnetic resonance studies, acquisition of which will allow the emulation of flow seen in duplex sonography. There is recently a growing interest in three-dimensional TEE. The acquisition of 3D images can be difficult even for experts in 2D TEE. It is planned to add a 3D TEE simulation module offering training also in this technique.

Acceptance of training in TEE and TTE with simulators has been shown to be very high among both novice and experienced echocardiographers [12, 13]. Because of that, different nature and ongoing improvements in the CT2TEE project we haven't conducted similar acceptance studies in our study. We assume however that even at the current stage of development the CT2TEE simulator is a valuable teaching tool allowing the complex process of learning TEE to be simplified and shortened.

References

1. Popescu BA, Andrade MJ, Badano LP, et al. European Association of Echocardiography recommendations for training, competence, and quality improvement in echocardiography. *Eur J Echocardiogr* 2009; 10: 893-905.
2. Thomas JD, Zoghbi WA, Beller GA, et al. ACCF 2008 Training Statement on Multimodality Noninvasive Cardiovascular Imaging A Report of the American College of Cardiology Foundation/American Heart Association/American College of Physicians Task Force on Clinical Competence and Training Developed in Collaboration With the American Society of Echocardiography, the American Society of Nuclear Cardiology, the Society of Cardiovascular Computed Tomography, the Society for Cardiovascular Magnetic Resonance, and the Society for Vascular Medicine. *J Am Coll Cardiol* 2009; 53: 125-46.
3. Prideaux D. Researching the outcomes of educational interventions: a matter of design. RTCs have important limitations in evaluating educational interventions. *BMJ* 2002; 324: 126-7.
4. Sedlack RE, Kolars JC. Computer simulator training enhances the competency of gastroenterology fellows at colonoscopy: results of a pilot study. *Am J Gastroenterol* 2004; 99: 33-7.
5. Wong AK. Full scale computer simulators in anesthesia training and evaluation. *Can J Anaesth* 2004; 51: 455-64.
6. Schijven M, Jakimowicz J. Construct validity: experts and novices performing on the Xitact LS500 laparoscopy simulator. *Surg Endosc* 2003; 17: 803-10.
7. McCloy R, Stone R. Science, medicine, and the future. Virtual reality in surgery. *BMJ* 2001; 323: 912-5.
8. Kutter O, Shams R, Navab N. Visualization and GPU-accelerated simulation of medical ultrasound from CT images. *Comput Methods Programs Biomed* 2009; 94: 250-66.
9. Van Herzele I, Aggarwal R, Malik I. Use of simulators in vascular training. *Heart* 2009; 95: 613-4.
10. Weidenbach M, Rzek V, Wild F, et al. Simulation of congenital heart defects: a novel way of training in echocardiography. *Heart* 2009; 95: 636-41.
11. Bose R, Matyal R, Panzica P, et al. Transesophageal echocardiography simulator: a new learning tool. *J Cardiothorac Vasc Anesth* 2009; 23: 544-8.
12. Weidenbach M, Drachsler H, Wild F, et al. EchoComTEE – a simulator for transoesophageal echocardiography. *Anaesthesia* 2007; 62: 347-53.
13. Weidenbach M, Wild F, Scheer K, et al. Computer-based training in two-dimensional echocardiography using an echocardiography simulator. *J Am Soc Echocardiogr* 2005; 18: 362-6.
14. Piorkowski A, Jajlesnica L, Szostek K. Creating 3D Web-Based Viewing Services for DICOM Images. 2009; 218-24.
15. Riddle WR, Pickens DR. Extracting data from a DICOM file. *Med Phys* 2005; 32: 1537-41.
16. Perloff JK, Warnes CA. Challenges posed by adults with repaired congenital heart disease. *Circulation* 2001; 103: 2637-43.
17. Quinones MA, Douglas PS, Foster E, et al. American College of Cardiology/American Heart Association clinical competence statement on echocardiography: a report of the American College of Cardiology/American Heart Association/American College of Physicians–American Society of Internal Medicine Task Force on Clinical Competence. *Circulation* 2003; 107: 1068-89.
18. Goyal SK, Punnam SR, Verma G, et al. Persistent left superior vena cava: a case report and review of literature. *Cardiovasc Ultrasound* 2008; 6: 50.

19. Douglas PS, Khandheria B, Stainback RF, et al. ACCF/AHA/ACEP/ASNC/SCAI/SCCT/SCMR 2007 appropriateness criteria for transthoracic and transesophageal echocardiography: a report of the American College of Cardiology Foundation Quality Strategic Directions Committee Appropriateness Criteria Working Group, American Society of Echocardiography, American College of Emergency Physicians, American Society of Nuclear Cardiology, Society for Cardiovascular Angiography and Interventions, Society of Cardiovascular Computed Tomography, and the Society for Cardiovascular Magnetic Resonance endorsed by the American College of Chest Physicians and the Society of Critical Care Medicine. *J Am Coll Cardiol* 2007; 50: 187-204.
20. Kaulitz R, Stumper OF, Geuskens R, et al. Comparative values of the precordial and transesophageal approaches in the echocardiographic evaluation of atrial baffle function after an atrial correction procedure. *J Am Coll Cardiol* 1990; 16: 686-94.
21. Crean A. Cardiovascular MR and CT in congenital heart disease. *Heart* 2007; 93: 1637-47.
22. Krishnamurthy R. The role of MRI and CT in congenital heart disease. *Pediatr Radiol* 2009; 39 (Suppl. 2): S196-204.